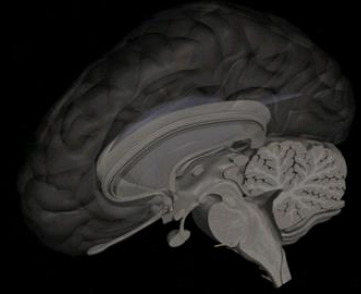


TUMORES CEREBRALES EN PEDIATRÍA

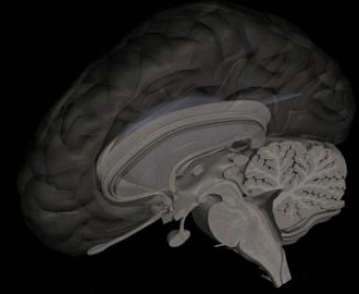
DR. PATRICIO GUERRA
NEURÓLOGO INFANTIL Y ADOLESCENTES
MAGÍSTER NEUROCIENCIAS
ESCUELA DE MEDICINA UNIVERSIDAD SAN SEBASTIÁN PUERTO MONTT



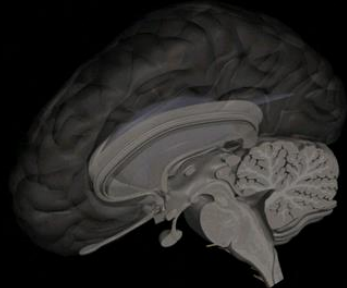
TUMORES CEREBRALES EN LA INFANCIA: OBJETIVOS DE LA CLASE

- SER CAPAZ DE IDENTIFICAR CLÍNICA DE TUMORES SEGÚN LOCALIZACIÓN ANATÓMICA DE ESTOS
- IDENTIFICAR SÍNTOMAS Y SIGNOS HABITUALES DE PRESENTACIÓN
- MANEJAR INDICACIONES DE ESTUDIOS DIAGNÓSTICOS EN TUMORES
- IDENTIFICAR RIESGOS GENERALES DE PACIENTES CON TUMORES CEREBRALES Y EL ENFRENTAMIENTO INICIAL DE ESTOS HASTA LA DERIVACIÓN
- IDENTIFICAR LA MORBILIDAD SECUELAR DE PACIENTES TRATADOS POR TUMORES CEREBRALES

TUMORES CEREBRALES EN LA INFANCIA



- PRIMERA CAUSA DE MUERTE EN EL CÁNCER INFANTIL
- SEGUNDO CÁNCER MÁS FRECUENTE DESPUÉS DE LOS HEMATOLÓGICO (PRIMERO EN TUMORES SÓLIDOS, 1 DE CADA 5 CÁNCERES INFANTILES)
- INCIDENCIA 5/100.000 POR AÑO
- PRESENTACIÓN DADA POR CEFALEA (1/3) Y SÍNTOMAS NEUROLÓGICOS
- TRATAMIENTO CLÁSICO: CIRUGÍA-RADIOTERAPIA-QUIMIOTERAPIA
- ESPERANZADORES AVANCES EN TERAPIAS BIOLÓGICAS
- SINTOMATOLOGÍA DADA SEGÚN UBICACIÓN ANATÓMICA DE LA LESIÓN
- MAYOR FRECUENCIA EN SÍNDROMES NEURO CUTÁNEOS
- NIÑOS PEQUEÑOS (0-4 AÑOS): MAYOR FRECUENCIA FOSA POSTERIOR



TUMORES CEREBRALES EN LA INFANCIA

-DIFERENTES TIPOS HISTOLÓGICOS, CLASIFICACIONES GENÉTICAS Y MOLECULARES PERMITEN APROXIMACIÓN ETIOLÓGICA Y TERAPEÚTICA

-GLIOMAS DE BAJO GRADO, UN TERCIO DE TC EN NIÑOS, QX ENFOQUE INICIAL: SOBREVIDA GLOBAL A 5 AÑOS 95%, LIBRE DE ENFERMEDAD 69%. DE NO SER POSIBLE QX, OBSERVACIÓN CON IMÁGENES CONTROL, RT-QT PUEDEN SER ALTERNATIVAS TERAPEÚTICAS

-ASTROCITOMA PILOCÍTICO, 20% TODO TC EN NIÑOS, SOBREVIDA A 10 AÑOS 90%

-GLIOMAS DE ALTO GRADO, 10% TC EN INFANCIA, 70-90% DE MORTALIDAD 2 AÑOS

-EPENDIMOMAS, 5-10% TC, 90% INTRACRANEALES, PERO TB.CEREBELO-ESPINALES TTO: QX, RT, A 10 AÑOS 50% SOBREVIDA, 30% LIBRES DE ENFERMEDAD

-TUMORES EMBRIONARIOS SNC (20% TC) : MEDULOBLASTOMAS (TUMOR MALIGNO MÁS FRECUENTE)

REVIEW ARTICLE

Allan H. Ropper, M.D., *Editor*

Brain Tumors in Children

Alan R. Cohen, M.D.

From the Department of Neurosurgery, Johns Hopkins University School of Medicine, Baltimore. Dr. Cohen can be contacted at alan.cohen@jhmi.edu or at Johns Hopkins University School of Medicine, Phipps Bldg., Rm. 556, 600 N. Wolfe St., Baltimore, MD 21287.

N Engl J Med 2022;386:1922-31.

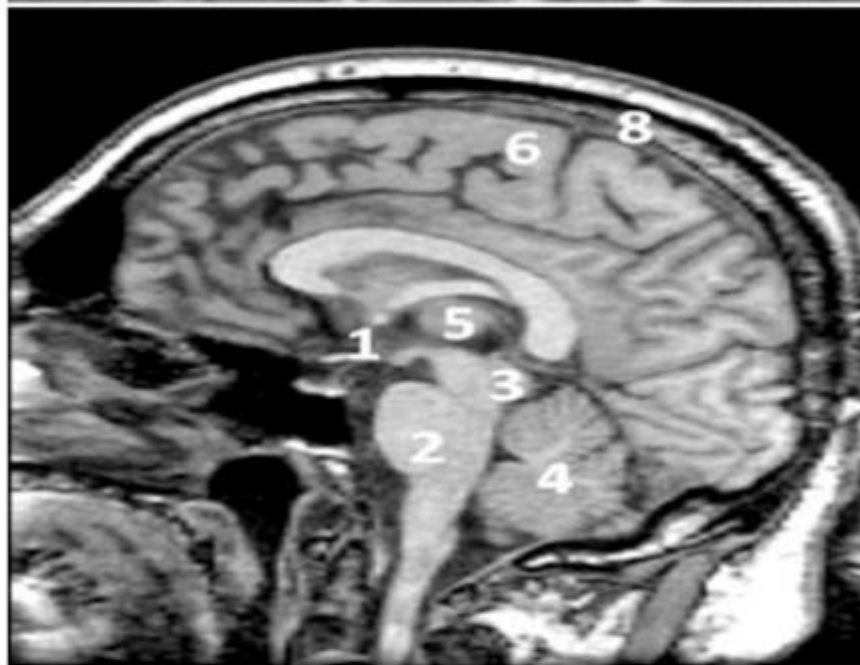
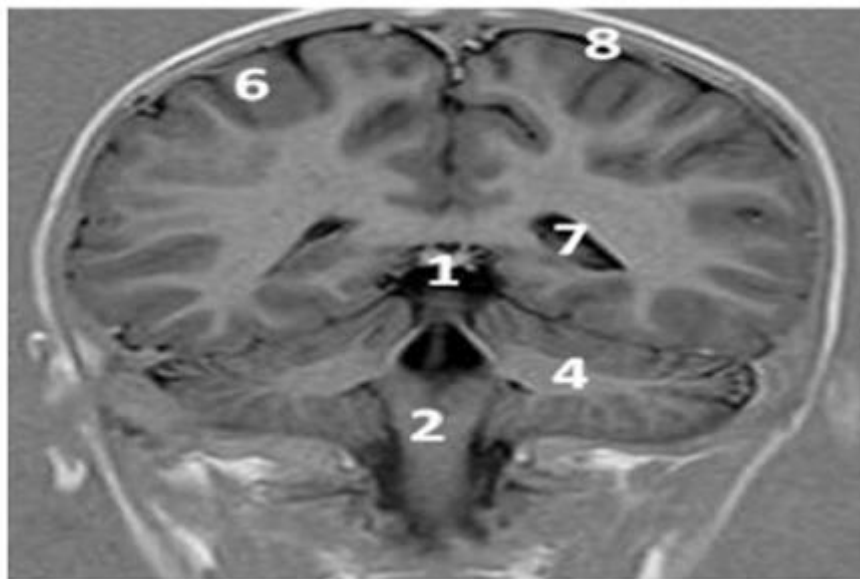
DOI: 10.1056/NEJMra2116344

Copyright © 2022 Massachusetts Medical Society.

CME
at [NEJM.org](https://www.nejm.org)

BRAIN TUMORS ARE THE MOST COMMON SOLID NEOPLASMS AND THE leading cause of death from cancer in children.¹⁻³ Tumors of the central nervous system (CNS) account for 20% of childhood cancers and are second only to leukemia in frequency.⁴ The average annual age-adjusted incidence of brain tumors in children in the United States is 5.65 cases per 100,000 population, with 0.72 deaths per 100,000 (among children who are newborn to 14 years old).³

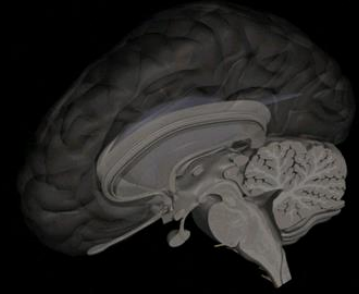
Recent diagnostic and therapeutic advances have led to improvement in survival and quality of life for many children with CNS cancers. However, the prognosis for many children with brain tumors remains poor, and treatments have long-term sequelae.^{2,5} This review highlights recent changes in the classification and management of brain tumors in children. Given the large number of such tumors and the complexity of new classification schemes, only the most common and representative types are discussed here.



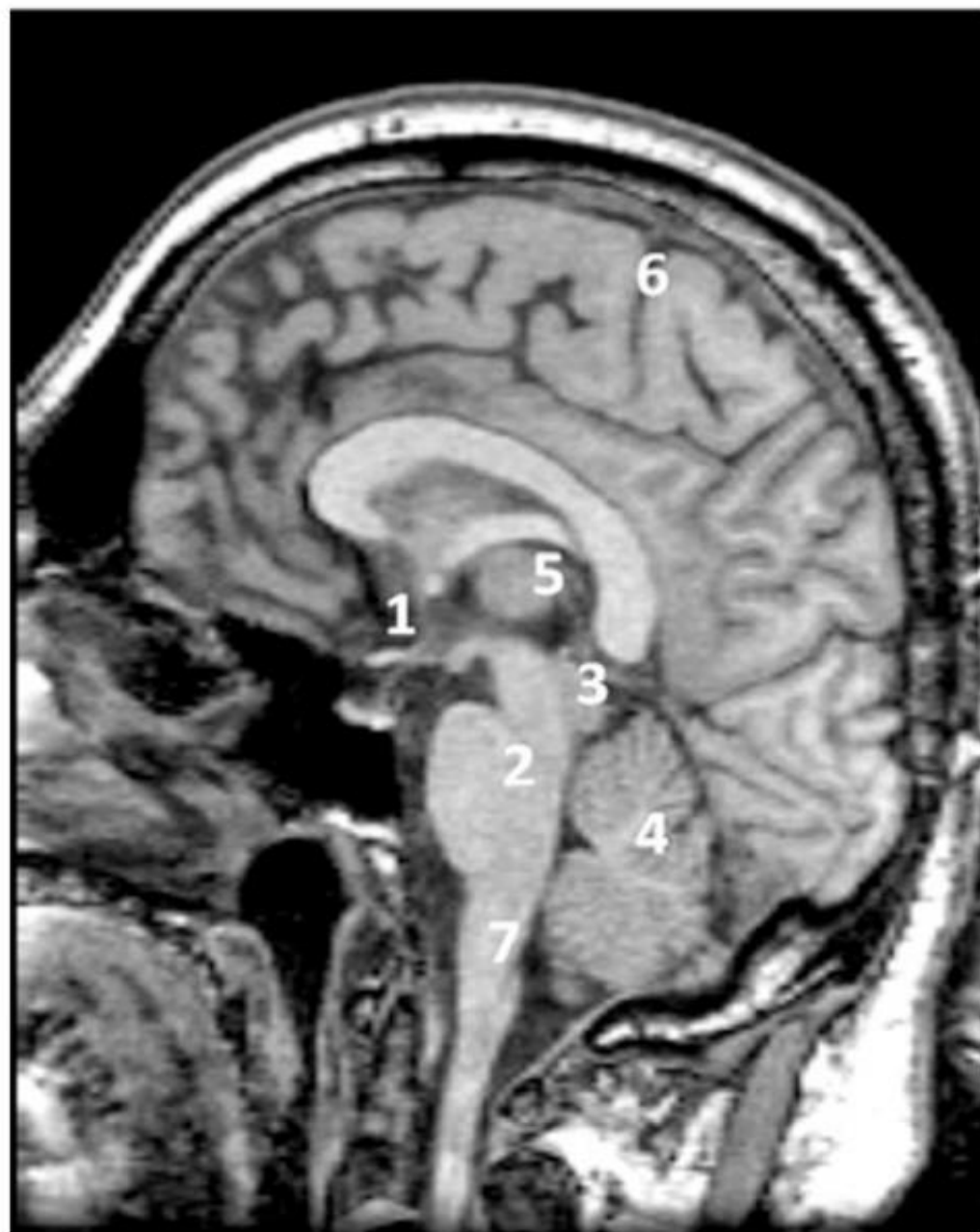1. **Suprasellar/chiasmatic:** optic glioma, craniopharyngioma, germinoma, prolactinoma, pituitary adenoma, pilomyxoid astrocytoma, Langerhans cell histiocytosis
2. **Pons:** diffuse intrinsic pontine glioma, focal low-grade/high-grade glioma
3. **Pineal gland/midbrain:** low-grade/high-grade glioma, pineoblastoma, pineocytoma, germinoma, primitive neuroectodermal tumor (PNET)
4. **Cerebellum:** medulloblastoma, juvenile pilocytic astrocytoma, ependymoma, atypical/atypical rhabdoid tumor (ATRT) high-grade glioma, hemangioblastoma, dysplastic gangliocytoma of the cerebellum
5. **Basal ganglia/thalamus:** low-grade/high-grade glioma, germinoma, oligodendroglioma
6. **Cortex:** low-grade/high-grade glioma, dysembryoplastic neuroepithelial tumor (DNET), PNET, ependymoma, oligodendroglioma, ganglioglioma, pleomorphic xanthoastrocytoma
7. **Ventricular system:** choroid plexus papilloma/carcinoma, subependymal giant cell astrocytoma, ependymoma, ATRT, desmoplastic infantile ganglioglioma (DIG)
8. **Meninges:** meningioma

Figure 1. Common pediatric brain tumor subtypes according to anatomic location.

SIGNOS Y SÍNTOMAS DE PRESENTACIÓN TUMORES CEREBRALES EN LA INFANCIA



- DEPENDIENTE UBICACIÓN TUMOR Y VÍAS COMPROMETIDAS
- CEFALEA: 1/3 DE PACIENTES ES SU SÍNTOMA DE PRESENTACIÓN, SIN EMBARGO SI NO SE RELACIONA A ALTERACIONES DEL EXAMEN NEUROLÓGICO U OTROS SÍNTOMAS, NO TIENE VALOR PREDICTIVO
- VÓMITOS: 1/3 DE PACIENTES LOS PRESENTAN AL MOMENTO DEL DIAGNÓSTICO
- EDEMA DE PAPILA: 15% EN NUEVOS DIAGNÓSTICOS DE TUMORES CEREBRALES
- TRIADA CLÁSICA: CEFALEA, VÓMITOS, TRASTORNOS DE LA MARCHA
MAYOR RELACIÓN CON TUMORES DE FOSA POSTERIOR
- FOSA POSTERIOR: TRIADA CLÁSICA, CEFALEA MATUTINA QUE AUMENTA AL LEVANTARSE
TORTÍCOLIS, CERVICOLATERALIZACIÓN
- TUMORES VÍA ÓPTICA Y SUPRASELARES: COMPROMISO CAMPO VISUAL
- REGIÓN HIPOTÁLAMO-HIPOFISIARIA: DISFUNCIÓN ENDOCRINA, RETRASO PUBERAL,
PUBERTAD PRECOZ, ANOREXIA, POLIURIA
- CORTEZA CEREBRAL: CONVULSIONES EN EL 40% DE TUMORES CORTICALES
(PERO...EN PRIMOCONVULSIONES AFEBRILES, SÓLO UN 4% SE RELACIONA A TUMORES)
- GANGLIOS BASALES: TICS, DISTONÍAS, TRASTORNOS MOVIMIENTO O COGNITIVOS
- MACROCEFALIA: NIÑOS PEQUEÑOS, ASOCIADA A SINTOMATOLOGÍA HTEC

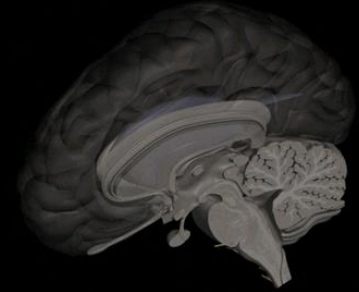


Symptoms of Pediatric Brain Tumors By Location

- 1. Suprasellar/chiasmatic:** visual field deficit, precocious/delayed puberty, anorexia, diabetes insipidus
- 2. Pons:** diplopia, facial weakness, drooling, weakness, incoordination, dysconjugate gaze
- 3. Pineal/midbrain tectum:** upgaze paralysis, vomiting, nystagmus, diplopia, tremor
- 4. Cerebellum:** vomiting, ataxia, tremor, dysmetria, nystagmus, scanning speech
- 5. Basal ganglia/thalamus:** movement disorder, weakness, hemisensory deficit, visual field deficit
- 6. Cortex:** seizures, weakness, disorder of language, encephalopathy, visual field deficit
- 7. Cervicomedullary junction:** head tilt, Horner syndrome, weakness, dysphagia, dysphonia, torticollis

Figure 2. Common symptoms of pediatric brain tumors according to anatomic location.

EXAMEN NEUROLÓGICO ANTE SOSPECHA TUMOR CEREBRAL



-AL MOMENTO DEL DIAGNÓSTICO, LA GRAN MAYORÍA DE LOS PACIENTES PRESENTA UN EXAMEN NEUROLÓGICO ALTERADO

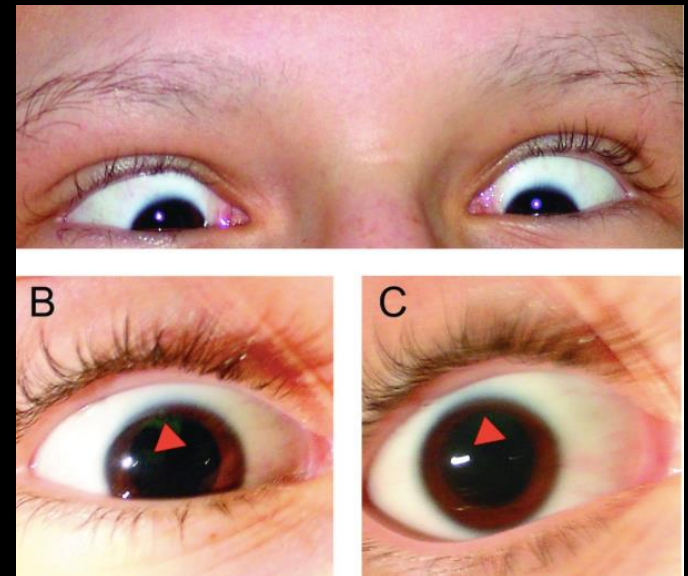
-CRUCIAL:

- EXAMEN MENTAL
- PARES CRANEALES (FONDO DE OJO, CAMPIMETRÍA)
- EXAMEN MOTOR
- EXAMEN SENSITIVO
- REFLEJOS (SIGNOS ARCAICOS)
- EXAMEN CEREBELOSO (COORDINACIÓN Y MARCHA)

-DETERIORO COGNITIVO DE LENTA INSTALACIÓN: LESIONES MESENCEFÁLICAS

-SEXTO PAR: SIN VALOR LOCALIZATORIO ANATÓMICO

-SÍNDROME DE PARINAUD: PARÁLISIS DE MIRADA VERTICAL, PUPILAS POSICIÓN INTERMEDIA CON POBRE RESPUESTA A LUZ, RETRACCIÓN DE LOS PÁRPADOS, NISTAGMO CONVERGENTE



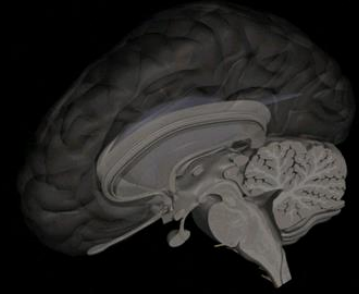
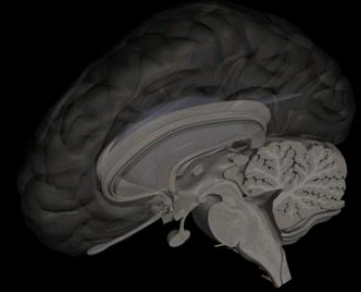


Table 2. Key Components of the Neurologic Examination in a Child Who Has a Suspected CNS Tumor

Examination	Pertinent Findings Suggestive of a Tumor
Mental status (level of alertness, speech and language)	Encephalopathy, progressive neurocognitive decline
Cranial nerve 2 (visual fields, fundoscopic examination)	Visual field deficit, papilledema
Cranial nerves 3, 4, 6 (extraocular movements, efferent pupillary function)	Nystagmus (upgaze in particular), gaze paralysis in any direction, mid-position, poorly reactive pupils
Cranial nerve 7 (facial symmetry)	Facial weakness (upper versus lower motor neuron distribution)
Cranial nerve 8 (hearing, balance)	Decreased hearing to finger rub (unilateral or bilateral), vertigo
Cranial nerves 9, 10, 12 (palate elevation, swallowing, tongue movements)	Drooling, dysphagia
Motor examination (bulk, tone, proximal and distal strength)	Early handedness, delayed motor milestones, pronator drift, focal changes in tone with associated atrophy
Reflexes (biceps, triceps, brachioradialis, patellar, Achilles)	Hyperreflexia with Babinski sign
Cerebellar function (finger to nose testing, mirror testing, rapid finger and toe tapping)	Dysmetria, overshoot on mirror testing, marked asymmetry of finger and/or toe tapping (must be differentiated from weakness)
Gait (heel, toe, tandem straight line)	Wide-based unsteady gait, inability to perform straight-line test, circumduction of gait
Sensory examination	Sensory deficits in a focal anatomic distribution

NEUROIMÁGENES



-URGENCIA: TAC CEREBRAL SIN CONTRASTE

-TAC NORMAL NO DESCARTA TOTALMENTE TUMORES CEREBRALES EN ESPECIAL TRONCOENCÉFALO, CEREBELO, SUPRASELAR O SUSTANCIA BLANCA

-TAC MUY ÚTIL EN DETECTAR SANGRE Y CALCIO

-RMN CEREBRAL: “GOLD STANDARD”

-PARA TODO NUEVO TUMOR CEREBRAL, RMN CEREBRAL Y COLUMNA TOTAL

-ESPECTROSCOPIA SIRVE PARA ESTUDIO DE METABOLITOS EN TEJIDO A ESTUDIAR

-DIFICULTADES RMN: DURACIÓN, METALES EN CUERPO, FUNCIÓN RENAL GADOLINIO, PUEDE NO DETECTAR SANGRE NI MINERALIZACIÓN

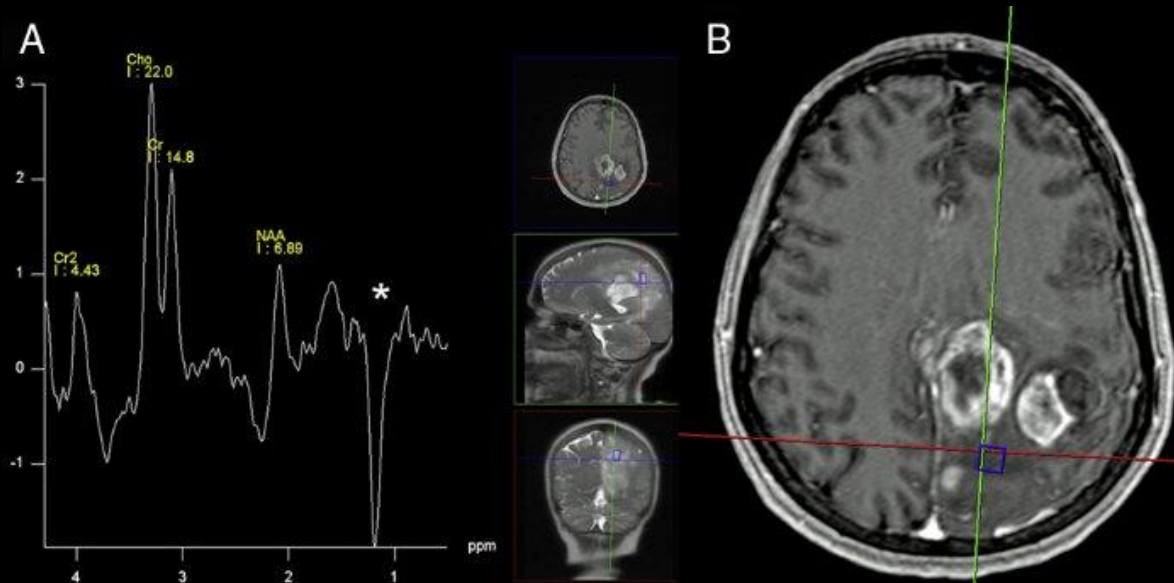


Table 3. **General Management Strategy of Newly Diagnosed Pediatric Brain Tumors**

Airway, breathing, circulation stabilization

Neurosurgery/neuro-oncology consultation

NPO

Presurgical laboratory tests (electrolytes, CBC, coagulation studies, blood type and cross-matching)

Intravenous steroids (dexamethasone) with GI-protective agent

Magnetic resonance imaging of the brain and spine with and without intravenous contrast

Preoperative endocrine laboratory tests for suprasellar tumors

Ophthalmologic examination

Seizure prophylaxis for patients presenting with or at high risk for convulsions

Social work consultation

Lumbar puncture for CSF cytology and tumor markers (for suspected CNS germinoma) is generally performed 7 to 10 days postoperatively if there are no contraindications.

CBC=complete blood cell count, CNS=central nervous system, CSF=cerebrospinal fluid, GI=gastrointestinal, NPO=nothing by mouth.

Table 4. Potential Late Effects of Pediatric Brain Tumor Therapy

1. Endocrinopathy (hypothyroidism, growth hormone deficiency, corticotropin deficiency, precocious or delayed puberty, diabetes insipidus)
2. Secondary neoplasms (hematogeneous, skin, thyroid, CNS)
3. Cerebral vasculopathy (stroke, Moyamoya disease, angiitis)
4. Neurocognitive effects (learning, memory, IQ)
5. Sensorineural hearing loss
6. Scoliosis
7. Osteopenia
8. Primary headache disorder
9. Epilepsy
10. Infertility/dysmenorrhea
11. Depression/anxiety
12. Obesity/diabetes
13. Neuropathy
14. Ocular effects (vision loss, amblyopia, cataracts)
15. Cardiomyopathy
16. Renal insufficiency

ORIGINAL ARTICLE

Oncolytic HSV-1 G207 Immunovirotherapy for Pediatric High-Grade Gliomas

G.K. Friedman, J.M. Johnston, A.K. Bag, J.D. Bernstock, R. Li, I. Aban, K. Kachurak, L. Nan, K.-D. Kang, S. Totsch, C. Schlappi, A.M. Martin, D. Pastakia, R. McNall-Knapp, S. Farouk Sait, Y. Khakoo, M.A. Karajannis, K. Woodling, J.D. Palmer, D.S. Osorio, J. Leonard, M.S. Abdelbaki, A. Madan-Swain, T.P. Atkinson, R.J. Whitley, J.B. Fiveash, J.M. Markert, and G.Y. Gillespie

ABSTRACT

BACKGROUND

Outcomes in children and adolescents with recurrent or progressive high-grade glioma are poor, with a historical median overall survival of 5.6 months. Pediatric high-grade gliomas are largely immunologically silent or “cold,” with few tumor-infiltrating lymphocytes. Preclinically, pediatric brain tumors are highly sensitive to oncolytic virotherapy with genetically engineered herpes simplex virus type 1 (HSV-1) G207, which lacks genes essential for replication in normal brain tissue.

METHODS

We conducted a phase 1 trial of G207, which used a 3+3 design with four dose cohorts of children and adolescents with biopsy-confirmed recurrent or progressive supratentorial brain tumors. Patients underwent stereotactic placement of up to four intratumoral catheters. The following day, they received G207 (10^7 or 10^8 plaque-forming units) by controlled-rate infusion over a period of 6 hours. Cohorts 3 and 4 received radiation (5 Gy) to the gross tumor volume within 24 hours after G207 administration. Viral shedding from saliva, conjunctiva, and blood was assessed by culture and polymerase-chain-reaction assay. Matched pre- and post-treatment tissue samples were examined for tumor-infiltrating lymphocytes by immunohistologic analysis.

RESULTS

Twelve patients 7 to 18 years of age with high-grade glioma received G207. No dose-limiting toxic effects or serious adverse events were attributed to G207 by the investigators. Twenty grade 1 adverse events were possibly related to G207. No virus shedding was detected. Radiographic, neuropathological, or clinical responses were seen in 11 patients. The median overall survival was 12.2 months (95% confidence interval, 8.0 to 16.4); as of June 5, 2020, a total of 4 of 11 patients were still alive 18 months after G207 treatment. G207 markedly increased the number of tumor-infiltrating lymphocytes.

CONCLUSIONS

Intratumoral G207 alone and with radiation had an acceptable adverse-event profile with evidence of responses in patients with recurrent or progressive pediatric high-grade glioma. G207 converted immunologically “cold” tumors to “hot.” (Supported by the Food and Drug Administration and others; ClinicalTrials.gov number, NCT02457845.)

The authors' full names, academic degrees, and affiliations are listed in the Appendix. Address reprint requests to Dr. Friedman at the Department of Pediatrics, University of Alabama at Birmingham, 1600 7th Ave. S., Lowder 512, Birmingham, AL 35233, or at gfriedman@peds.uab.edu.

This article was published on April 10, 2021, at NEJM.org.

DOI: 10.1056/NEJMoa2024947
Copyright © 2021 Massachusetts Medical Society.

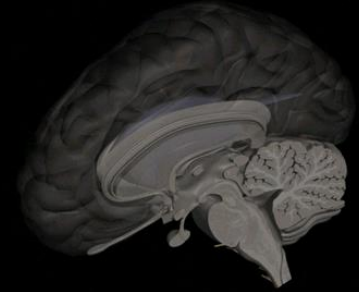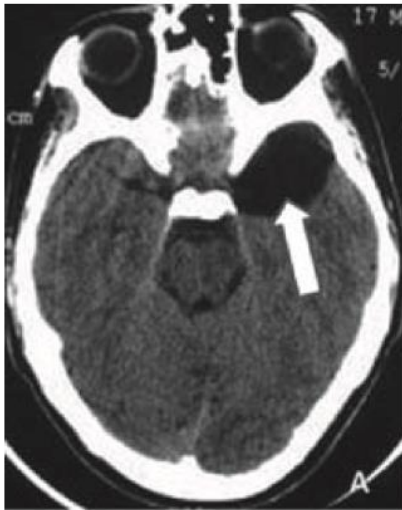
QUISTES ARACNOIDALES

-1% DE LESIONES INTRACRANEALES CON EFECTO DE MASA

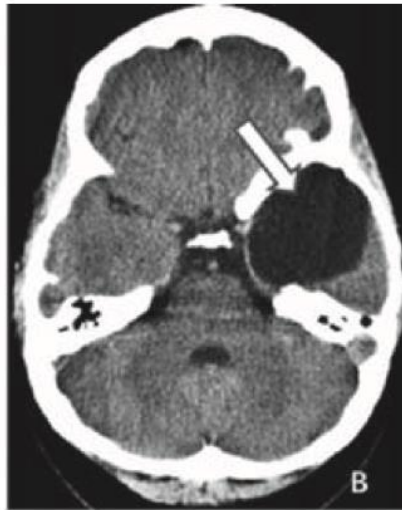-ORIGEN CONGÉNITO EMBRIONARIO)

-CONTENIDO SIMILAR AL LCR, FRECUENTEMENTE CONECTADOS A ESPACIO SUBARACNOÍDEO, POR LO TANTO, UBICACIÓN EXTRACEREBRAL

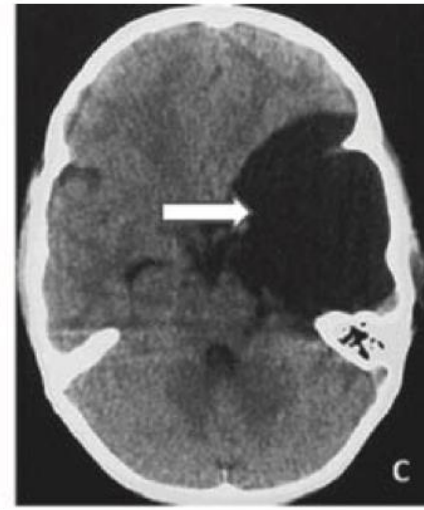
-DIAGNÓSTICO RADIOLÓGICO, LA MAYORÍA DE LAS VECES, HALLAZGO INCIDENTAL



Tipo I: Quiste cuadrangular situado en la cara anterior del lóbulo temporal sin aparente efecto masa.



Tipo II: Quiste de tamaño medio, localizado en la parte anterior y media de la fosa temporal y con frecuencia comprime el lóbulo temporal.



Tipo III: Quiste de forma oval o redondeada que ocupa la totalidad de la fosa temporal y tiene un gran efecto masa.

Figura 2. Imágenes axiales por tomografía de cráneo en las que se aprecian quistes aracnoideos de la fosa media de acuerdo con la clasificación de Galassi.

QUISTES ARACNOIDALES

- OCASIONALMENTE ORIGINAN SINTOMATOLOGÍA (CEFALEA)
- DIAGNÓSTICO: TAC CEREBRAL , RMN CEREBRAL COMPLEMENTARIA
- MUY OCASIONALMENTE SON COMPRESIVOS DE ESTRUCTURAS VECINAS Y REQUIEREN CIRUGÍA (FENESTRACIÓN)

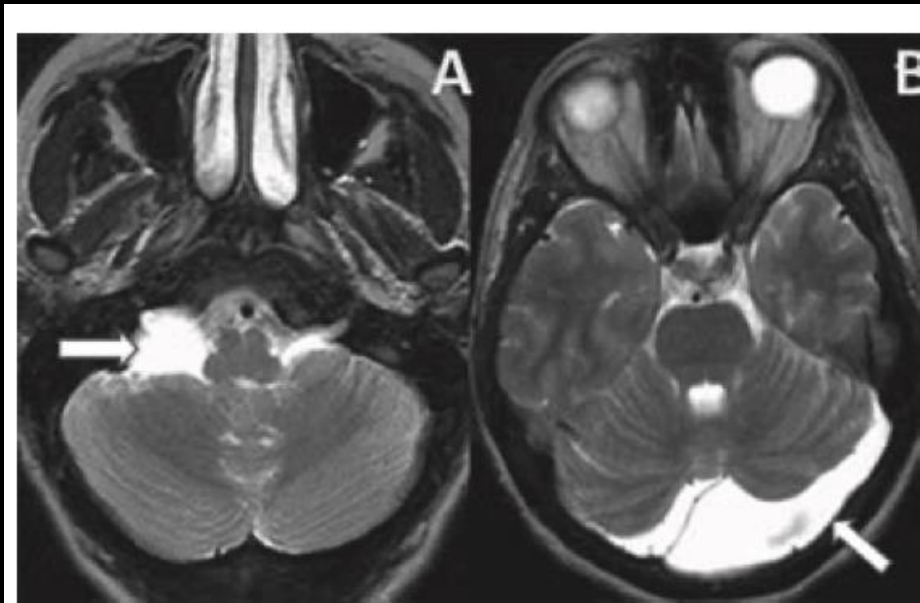
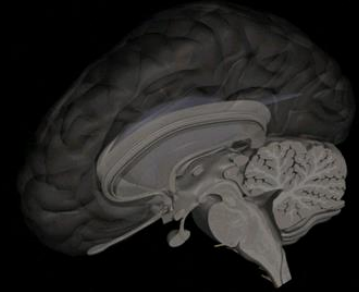
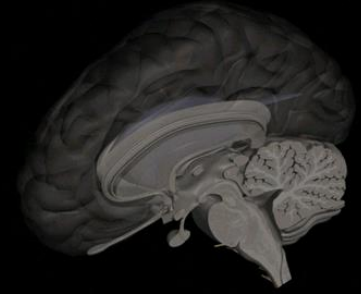


Figura 3. Imagen axial T2 por resonancia magnética de cráneo. A) Quiste aracnoideo en el ángulo pontocerebeloso. B) Quiste aracnoideo retrocerebeloso.

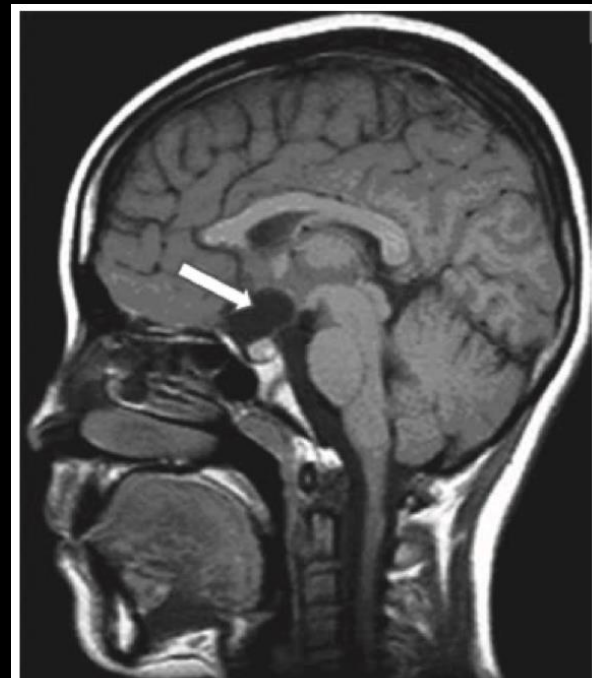

Figura 1. Imagen sagital T1 por resonancia magnética de cráneo donde se observa un quiste aracnoideo en la región supraselar que comprime el quiasma óptico.



TUMORES CEREBRALES EN LA INFANCIA: OBJETIVOS DE LA CLASE



- SER CAPAZ DE IDENTIFICAR CLÍNICA DE TUMORES SEGÚN LOCALIZACIÓN ANATÓMICA DE ESTOS
- IDENTIFICAR SÍNTOMAS Y SIGNOS HABITUALES DE PRESENTACIÓN
- MANEJAR INDICACIONES DE ESTUDIOS DIAGNÓSTICOS EN TUMORES
- IDENTIFICAR RIESGOS GENERALES DE PACIENTES CON TUMORES CEREBRALES Y EL ENFRENTAMIENTO INICIAL DE ESTOS HASTA LA DERIVACIÓN
- IDENTIFICAR LA MORBILIDAD SECUELAR DE PACIENTES TRATADOS POR TUMORES CEREBRALES

JACK NICHOLSON MORGAN FREEMAN



UNA PELÍCULA DE ROB REINER

ANTES DE PARTIR



“Divertidísima y profundamente reconfortante.”

- Tim Estiloz, THE COMCAST NETWORK